

Augmented Reality Microscopy (ARM) Utility for Breast Tumor Measurements

Mustafa Yousif MD, Liron Pantanowitz MD MHA

Department of Pathology, University of Michigan Health System, Ann Arbor, Michigan

INTRODUCTION

Pathology reports about breast carcinoma require pathologists to accurately measure tumor size, distance to surgical margins, and the size of lymph node metastases. This study aimed to assess whether novel Augmented Reality Microscopy (ARM) (figure 1) was easier to use and more accurate to obtain these measurements compared to using a ruler with a Manual Optical Microscope (MOM) and annotation with Whole Slide Imaging (WSI).

MATERIALS AND METHODS

Thirty archival cases of breast cancer were reviewed including 10 invasive ductal carcinomas (IDC), 10 with ductal carcinoma in situ (DCIS), and 10 with lymph node (LN) metastases. All measurements were compared in the same manner using MOM (Olympus BX43 light microscope), ARM (Augmentiqs) (figure 3) and WSI (ImageScope viewer, Leica). Concordance was defined as ≤ 0.2 mm difference.

FIGURE 1




Fig 1 Olympus BX43 light microscope with the Augmentiqs device (red circle) fitted between the objective lenses and the eyepiece.

FIGURE 2

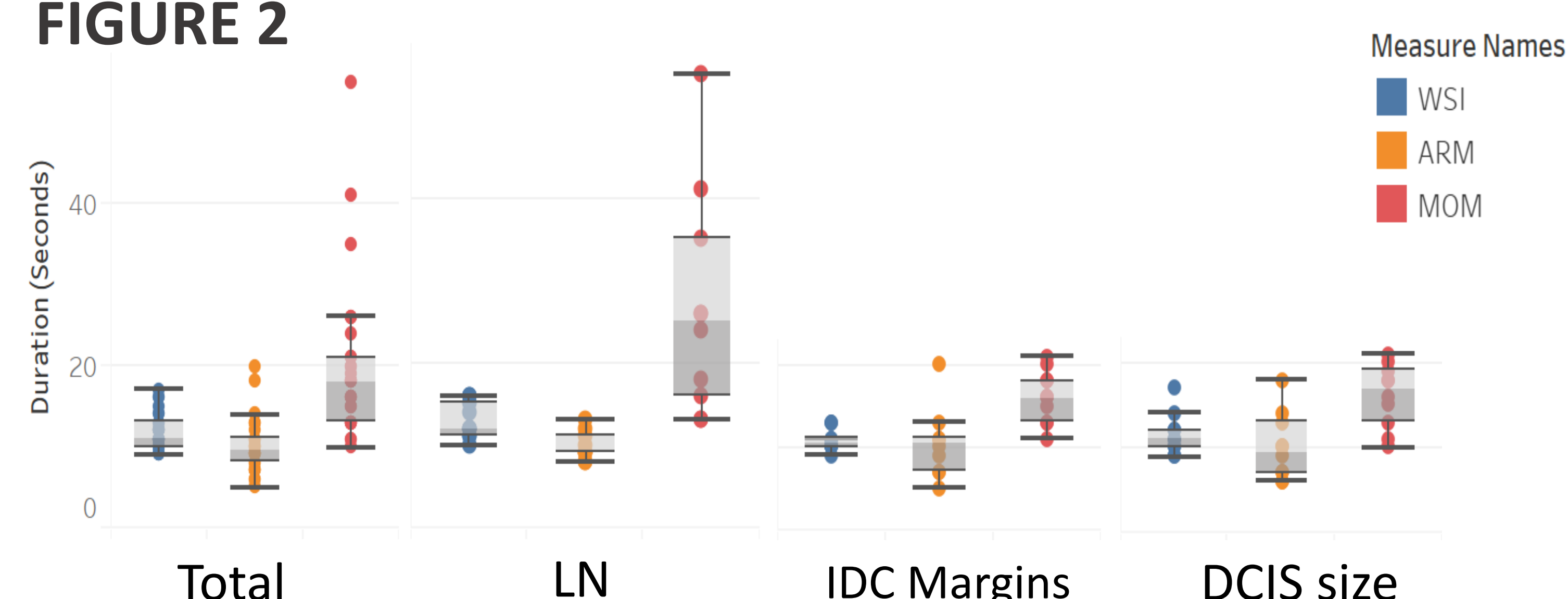


Fig 2 Box plot of WSI, ARM and MOM. (LN = lymph node, IDC = invasive ductal carcinomas, and DCIS = ductal carcinoma in situ).

FIGURE 3

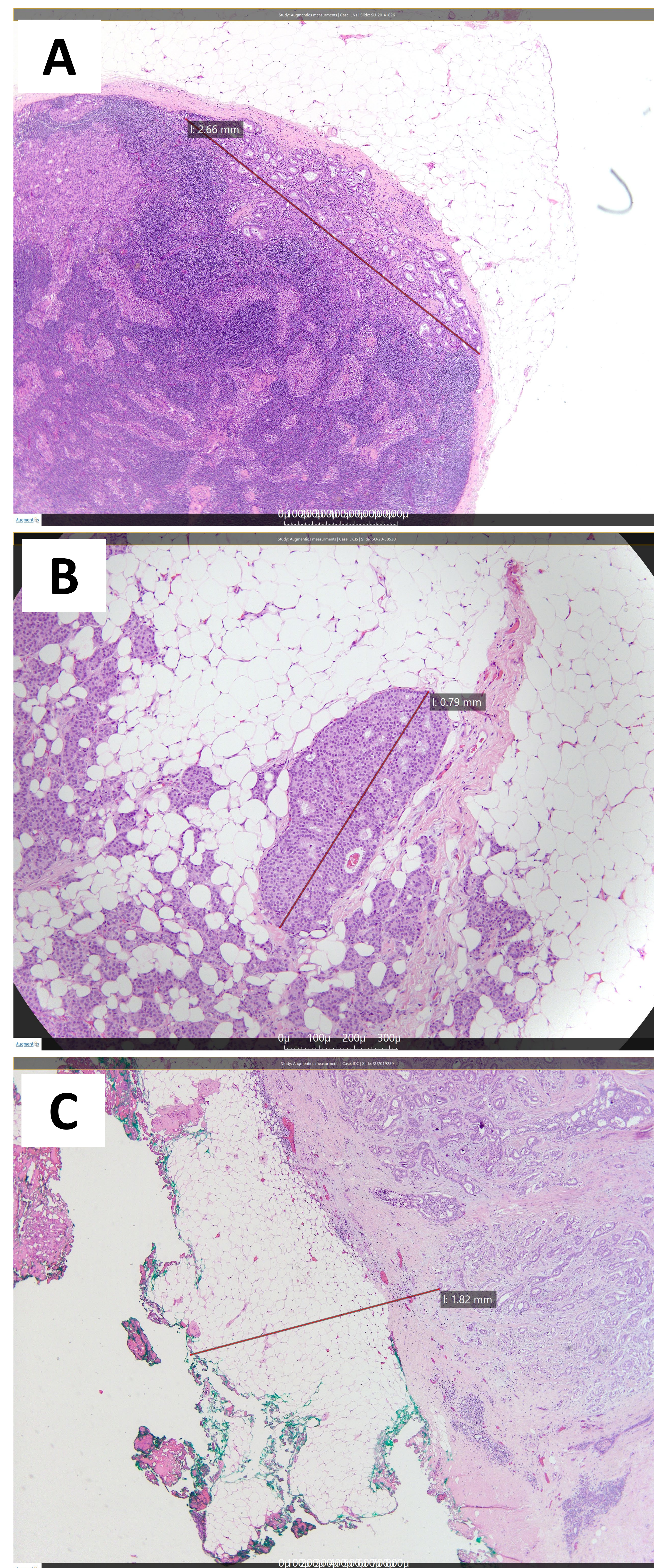


Fig 3 Measurements taken by ARM (A) LN metastasis, (B) DCIS size, and (C) IDC extension to resection margin. (LN = lymph node, DCIS = ductal carcinoma in situ, and IDC = invasive ductal carcinomas).

RESULTS

All (100%) cases showed concordance between ARM and WSI measurements with 1.0 INTERCLASS CORRELATION COEFFICIENT (ICC), 95% CI (99, 100), and 80% showed concordance between MOM and WSI (Table 1). Measurements ≤ 0.5 mm were most challenging with the MOM method, especially at 20x magnification. At low magnification (2x and 4x) WSI measurements were most challenging. MOM measurements were most time-consuming, while ARM was the fastest method followed by WSI (figure 2, and 4).

FIGURE 4

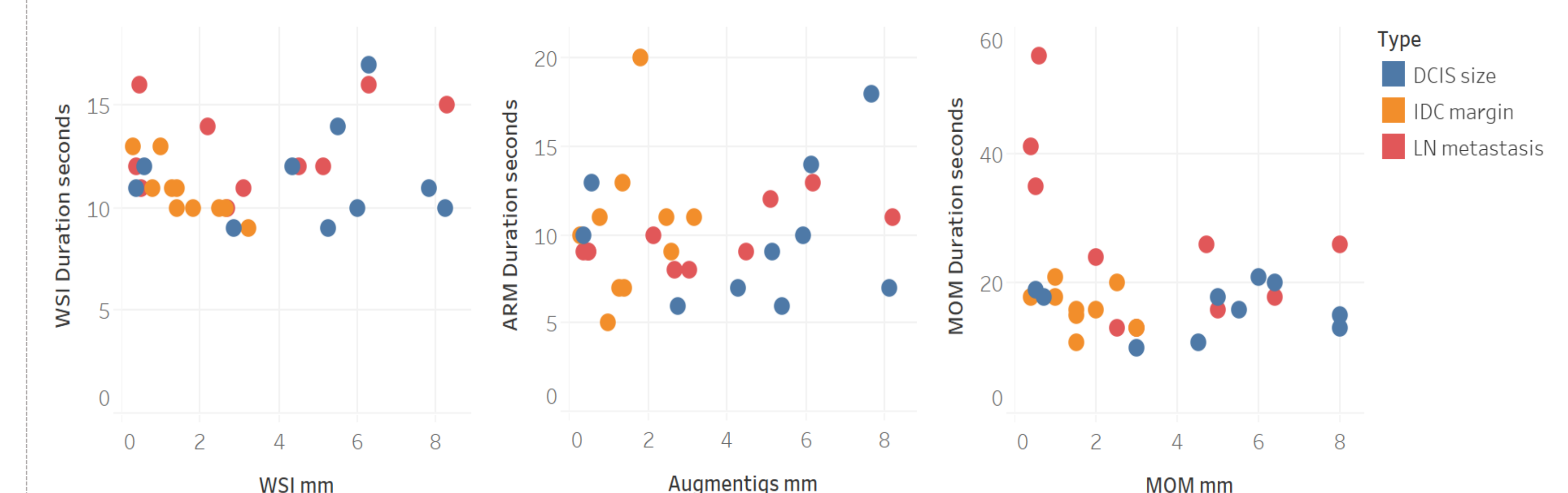


Fig 4 Scatterplots of time spent versus the measurements for different assessment methods. ARM indicates augmented reality microscopy; WSI, whole slide images; MOM, Manual Optical Microscope. (LN = lymph node, DCIS = ductal carcinoma in situ, and IDC = invasive ductal carcinomas).

Measurements Methods	ICC	Lower95	Upper95
WSI vs. ARM vs. MOM	0.998	0.997	0.999
WSI vs. ARM	1.000	0.999	1.000
WSI vs. MOM	0.998	0.996	0.999

Table 1 Interclass Correlation Coefficient results for the measurements of different assessment methods.

CONCLUSIONS

ARM required no prior digitization of slides, was easy to use and quicker than MOM, and was as accurate as WSI when measuring breast tumor size, distance to margins, and size of lymph node metastases.